ScienceDirect

View PDF

Brain Hemorrhages

Available online 10 October 2023

In Press, Journal Pre-proof What's this?

Recommended articles

No articles found.

Case Report

An extensive basal ganglia hemorrhage in a preexisting neonatal asphyxiated lesion after mRNA-based SARS-CoV-2 vaccination: A fatal adult case of cerebral palsy

Tomoyuki Takano [a b], Masahiro Ito [a]

Show more

Outline | Add to Mendeley Share Cite

https://doi.org/10.1016/j.hest.2023.10.001 Get rights and content

Under a Creative Commons license open access

Abstract

Objective

Neurological adverse reactions to SARS-CoV-2 vaccines include a wide variety of central nervous system (CNS) disorders; however, the cause-and-effect relationship is unclear. Herein, we present a fatal case of extensive basal ganglia bleeding after mRNA-based SARS-CoV-2 vaccination and discuss the pathophysiological mechanisms of brain hemorrhage.

Case presentation

A 66-year-old woman with cerebral palsy and a history of neonatal asphyxia suddenly presented with hypothermia and consciousness disturbance one day after the sixth dose of an mRNA-based SARS-CoV-2 vaccine (Moderna). Clinical investigations revealed a normal thrombocyte count, but stage 1 hypertension and mild prolongation of the prothrombin time and activated partial thromboplastin time. Urgent brain computed tomography (CT) revealed extensive left basal ganglia hemorrhage with global brain edema and downward herniation of the brainstem. The region of the large hematoma corresponded to the basal ganglia lesion which had been produced by neonatal asphyxia at birth. Because the neurosurgeons evaluated her state as inoperable, conservative therapy was continued, but the patient died on day 5 after the event.

Conclusion

We hypothesized that two pathophysiological mechanisms were responsible for the brain hemorrhage in this case: disruption of focal cerebrovascular autoregulation in preexisting neonatal asphyxiated lesions and disturbance of coagulation pathways after mRNA-based SARS-CoV-2 vaccination.

Keywords

SARS-CoV-2; Vaccine; Brain hemorrhage; Neonatal asphyxia; Vascular autoregulation; Basal ganglia

Introduction

Neurological adverse reactions to SARS-CoV-2 vaccines include a wide variety of central nervous system (CNS) disorders, ranging from mild to fatal. Among cerebrovascular diseases, venous sinus thrombosis, ischemic stroke, and intracerebral hemorrhage have been reported as frequent CNS complications after SARS-CoV-2 vaccination.[1] The pathogenetic mechanisms of these complications are variable depending on the type of vaccine and underlying diseases of the patients. However, it has not been clarified in detail whether there is a cause-and-effect relationship between CNS disorders and SARS-CoV-2 vaccines. We herein report a fatal case of basal ganglia hemorrhage with ventricular rupture that occurred shortly after the administration of a sixth dose of an mRNA-based SARS-CoV-2 vaccine, and discuss the pathophysiological mechanisms of brain hemorrhage after vaccination. This case involved an adult woman with cerebral palsy who was hospitalized in our residential facility and had a history of neonatal asphyxia at birth.

Case presentation

The female patient was born to non-consanguineous parents at term, with a body weight of 2625 g after vaginal delivery. Due to cephalopelvic disproportion, labor was prolonged, and the patient delivered profound asphyxiate. Postdelivery, the infant showed global developmental delay and mental retardation and was diagnosed with cerebral palsy before 6 months of age. At 17 years of age, she was admitted to the Biwako-Gakuen Residential Facility Hospital, where medical and welfare treatment was provided to individuals with intellectual and physical disabilities. Because of their profound disabilities, most people at this facility need to be hospitalized for their entire life. On admission, she manifested severe movement and postural abnormalities (predominantly spastic quadriplegia), characterized by a generalized increase in muscle tone. The legs were more involved than the arms, and a paucity of limb movements was characteristic. At 65 years and 6 months of age, brain computed tomography (CT) was performed as a routine neuroradiological evaluation, which showed cortical atrophy of the left frontal and temporal lobes and low-density lesions in the left caudate nucleus, putamen, and globus pallidus (Fig. 1A). These lesions are thought to be induced by neonatal asphyxia at birth, although there was no magnetic resonance imaging (MRI) evidence to prove this had been present since birth.

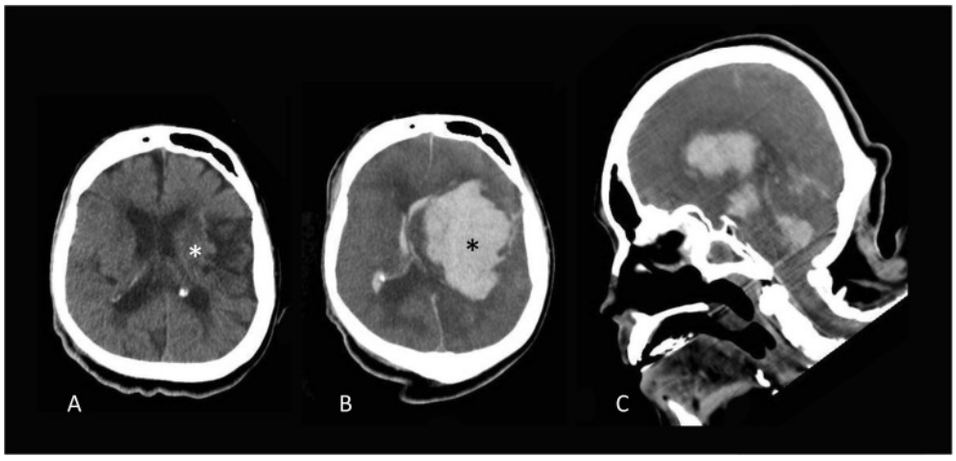

Download : Download high-res image (359KB)

Download : Download full-size image

Fig. 1. Brain CT performed as a routine evaluation at 65 years and 6 months of age (A), and as an urgent evaluation to investigate the cause of deep coma at 66 years and 8 months of age (B, C).A: Low-density lesions in the left basal ganglia (white asterisk) were found, which were caused by neonatal asphyxia at birth. B: Note the extensive intracranial hematoma in the left basal ganglia (black asterisk) and region corresponding to the asphyxiated basal ganglia lesion (white asterisk in A).C: Bleeding in the basal ganglia ruptured into the lateral ventricles, expanding to the fourth ventricle with global brain edema, resulting in downward herniation of the brainstem.

At 66 years and 8 months of age, she suddenly presented with hypothermia and consciousness disturbance one day after the sixth dose of an mRNA-based SARS-CoV-2 vaccine (Moderna). She had not experienced any side effects after the first to fifth vaccinations (four times with Biontech/Pfizer and one time with Moderna); her vaccination record is summarized in Table 1. She had a history of congestive heart failure due to atrial fibrillation 12 months previously, and had been treated with anticoagulants, β-blockers, loop diuretics, and angiotensin-converting enzyme inhibitors until the present urgent event. She also had several comorbid disorders with cerebral palsy, including hypermuscle tonus treated with muscle relaxants, costal and vertebral fractures due to osteoporosis, chronic respiratory failure treated with mechanical ventilation, and urolithiasis due to a neurogenic bladder. Clinical examination revealed a deep coma with a Glasgow Coma Scale of 3, hypothermia (body temperature, 32.2 °C), normal heart rate (59/min), and stage 1 hypertension (blood pressure, 131/78 mmHg). Blood tests revealed mild anemia (erythrocyte 328 × 10^4/μL, hemoglobin 10.2 g/dL, hematocrit 30.8 %), normal thrombocyte count (29.0 × 10^4/μL), mild prolongation of prothrombin time (18.6 s), and activated partial thromboplastin time (40.1 s). Urgent brain CT showed extensive intracranial hemorrhage in the left basal ganglia region involving the head to tail of caudate nucleus and putamen, which ruptured into the lateral ventricles expanding to the fourth ventricle with global brain edema and resultant downward herniation of the brainstem (Fig. 1B, 1C). The entire area of this large hematoma corresponded to the basal ganglia lesion, which was caused by perinatal asphyxia at birth. Because the neurosurgeons judged the patient's condition to be inoperable, conservative therapy was continued, but the patient died on day 5 after the event.

Table 1. The patient's SARS-CoV-2 vaccination records.

Number	Date (year/month/day)	Vaccine		
		Company	Genetic name	Technolog
1	2021/5/27	Biontech/Pfizer	BNT162b2	mRNA
2	2021/6/16	Biontech/Pfizer	BNT162b2	mRNA
3	2022/2/15	Biontech/Pfizer	BNT162b2	mRNA
4	2022/9/6	Moderna	m-RNA1273	mRNA
5	2023/2/20	Biontech/Pfizer	BNT162b2	mRNA
6	2023/6/13	Moderna	m-RNA1273	mRNA

Discussion

Disruption of vascular autoregulation in the

asphyxiated brain

Hypoxic-ischemic brain injury in term infants has three major patterns of neuronal injury: diffuse, cerebrocortical-deep nuclear, and deep nuclear-brainstem patterns.[2] MRI studies of asphyxiated term infants suggest that approximately 35–85 % exhibit predominantly cerebral-deep nuclear neuronal involvement, including basal ganglia (especially putamen) and thalamus.[2] The pre-existing brain lesion of the basal ganglia in the present case (Fig. 1A) showed a particular pattern of asphyxiated injury observed in term newborns. In a study of asphyxiated infants with the poorest outcomes, cerebral blood flow (CBF) was reported to be passively related to arterial blood pressure due to impaired vascular autoregulation.[3] Cerebrovascular autoregulation is expressed as the reactivity of CBF to changes in mean arterial blood pressure, which holds CBF relatively constant across changes in cerebral perfusion pressure.[4] Four mechanisms have been proposed for cerebrovascular autoregulation:1) myogenic, 2) neurogenic, 3) metabolic, and 4) endothelial mechanisms. The myogenic component concerns the ability of the vascular smooth muscle to constrict or dilate in response to changes in the transmural pressure. Neurogenic mechanisms occur through extensive nerve supply to the cerebral vessels. The metabolic mechanism probably contributes to autoregulation in the microvasculature, where changes in the microenvironment, such as pCO_2 and H^+, lead to vasodilation. Additionally, endothelial factors such as nitric oxide may also contribute to autoregulation. Autoregulation is important for matching CBF to metabolic demands.[5] Based on these considerations for exhaustive vascular mechanisms, it is suggested that the asphyxiated brain lesion in the present case may have some functional defects in operating complete focal cerebrovascular autoregulation.

Variable mechanisms of adverse effects after SARS-CoV-2 vaccinations

There are three major strategies for producing SARS-CoV-2 vaccines: mRNA, viral vector, and inactivated protein subunit vaccines. mRNA vaccines contain the mRNA of the antigen of interest that enters cells and is translated into the spike protein to induce an immune response. Viral vector vaccines have delivery systems that contain nucleic acids that encode antigens and induce the production of viral proteins. These viral proteins are identified as antigens that stimulate antibody production. Inactivated vaccines are viruses that cannot infect or replicate in cells. However, viral particles and proteins are recognized as antigens that trigger the immune system.[6]

Inactivated and protein subunit vaccines

Few and scattered reports have been published on the side effects of inactivated virus-based vaccines. Vaccine reactivity has been linked to a temporary increase in inflammatory cytokines that act on blood vessels, muscles, and other tissues.[7] According to the World Health Organization (WHO), in the case of side effects of inactivated virus-based vaccines, the most common local and systemic adverse reactions are injection site reactions, fatigue, fever, headache, and allergic dermatitis, which are self-limiting, and the patient experiencing these side effects does not need to be hospitalized.[8].

Viral vector vaccines

Primary SARS-CoV-2 infection with systemic viral RNA release contributes to innate immune coagulation cascade activation with both pulmonary and systemic immunothrombosis, manifesting as chest pain, pulmonary embolism, systemic thrombosis, stroke, cardiac and renal ischemia affecting both arterial and venous territories.[9], [10] A brief clinical investigation of five patients who showed venous thrombosis and thrombocytopenia 7–10 days after receiving the first dose of the adenoviral vector vaccine has been reported, in which the authors referred to the condition as vaccine-induced immune thrombotic thrombocytopenia (VITT).[11] These thrombotic disorders are reminiscent of natural SARS-CoV-2 infection[12]. The worst outcome of neurological complications caused by SARS-CoV-2 vaccines is cerebral venous sinus thrombosis after vaccination with vector-based vaccines,[13] especially for women.[14] The proposed mechanism of thrombocytopenia is the synthesis of IgG antibodies against platelet factor 4 (PF4), which activates platelets and blood clots in large venous arteries, resulting in a state that clinically mimics heparin-induced thrombocytopenia.[15], [16].

mRNA vaccines

mRNA vaccines as well as adenovirus-based vaccines can induce various acute neurological disorders, including transverse myelitis, Guillain-Barre syndrome, Bell's palsy, acute disseminated encephalomyelitis, encephalopathy, and intracerebral hemorrhage.[16] Some possible mechanisms of these brain disorders have been suggested, such as the synthesis and release of spike proteins causing severe inflammation, increased glial activity, the resultant increased permeability of the blood–brain barrier, destruction of myelin, associated axonal degeneration, and reactivation of varicella-zoster virus after vaccination[17], [18]. In the present case, the relationship between the disturbance of coagulation pathways and adverse effects of mRNA vaccines has not yet been clarified; however, it is noteworthy that increased permeability of the blood–brain barrier can be induced after mRNA vaccination. These events can induce the entry of peripheral blood cells and albumin into the brain parenchyma, resulting in disruption of osmotic balance in the brain, which is closely associated with brain hemorrhage.

Conclusion

We describe a fatal adult case of cerebral palsy manifesting as extensive basal ganglia hemorrhage after receiving an mRNA-based SARS-CoV-2 vaccination. The region of the large hematoma after bleeding corresponded to the basal ganglia lesion that had been produced by neonatal asphyxia at birth. Clinical investigations revealed a normal thrombocyte count, but stage 1 hypertension and mild prolongation of the prothrombin time and activated partial thromboplastin time, thus indicating a functional disturbance of the extrinsic, intrinsic, and common pathways of coagulation. We suggest two factors for the pathophysiological mechanisms of the brain hemorrhage observed in this case: the disruption of focal cerebrovascular autoregulation in preexisting neonatal asphyxiated lesions and the disturbance of coagulation pathways after mRNA-based SARS-CoV-2 vaccination.

Funding

This research did not receive any specific grants from the funding agencies.

Ethics approval

This study was approved by the ethics committee of the Biwako-Gakuen Medical and Welfare Center of Yasu.

Consent to participate

The requirement for informed consent was waived by the ethics committee, as it was a non-interventional retrospective study that used only information from medical records, without individual identification of the participant. The patient subsequently died.

Author's contribution

The authors (T. T. and M. I.) contributed equally to the conception, drafts, and final version of this article.

Declaration of Competing Interest

The authors declare that they have no known competing financial interests or personal relationships that could have appeared to influence the work reported in this paper.

Acknowledgments

The authors gratefully acknowledge the medical staff of the Biwako-Gakuen Medical and Welfare Center of Yasu (Dr. Keisuke Ohshima, Dr. Takahiro Ito, Dr. Yuki Harada, Dr. Katsuhiko Ogawa, Dr. Masaki Ohno, Dr. Eiko Koyama, and Dr. Shosaku Yamazaki) for their clinical contribution. The authors also acknowledge Mr. Hideki Iwata (Division of

Radiology) for collecting and analyzing patient information.

References

[1] J. Finsterer
Neurological adverse reactions to SARS-CoV-2 vaccines
Clin Psychopharmacol Neurosci, 21 (2) (2023), pp. 222-239
CrossRef ↗ View in Scopus ↗
Google Scholar ↗

[2] H.C. Kinney, J.J. Volpe
Hypoxic-ischemic injury in the term infant: neuropathology
J.J. Volpe, T.E. Inder, B.T. Darras (Eds.), Volpe's neurology of the newborn (6th ed.), Elsevier (2018), pp. 484-499
View PDF View article Google Scholar ↗

[3] J.J. Volpe
Hypoxic-ischemic injury in the term infant: pathophysiology
J.J. Volpe, T.E. Inder, B.T. Darras (Eds.), Volpe's neurology of the newborn (6th ed.), Elsevier (2018), pp. 500-509
View PDF View article Google Scholar ↗

[4] C.J. Rhee, C.S. da Costa, T. Austin, *et al.*
Neonatal cerebrovascular autoregulation
Pediatr Res, 84 (2018), pp. 602-610
CrossRef ↗ View in Scopus ↗
Google Scholar ↗

[5] W.M. Armstead
Cerebral blood flow autoregulation and dysautoregulation
Anesthesiol Clin, 34 (3) (2016), pp. 465-477
View PDF View article View in Scopus ↗
Google Scholar ↗

[6] T. Fiolet, Y. Kherabi, C.-J. MacDonald, *et al.*
Comparing COVID-19 vaccines for their characteristics, efficacy and effectiveness against SARS-CoV-2 and variants of concern: a narrative review

Clin Microbiol Infect, 28 (2022), pp. 202-221

View PDF View article View in Scopus ↗

Google Scholar ↗

[7] Y. Zhang, G. Zeng, H. Pan, *et al.*

Safety, tolerability, and immunogenicity of an inactivated SARS-CoV-2 vaccine in healthy adults aged 18–59 years: a randomized, double-blind, placebo-controlled, phase 1/2 clinical trial

Lancet Infect Dis, 21 (2) (2021), pp. 181-192

View PDF View article Google Scholar ↗

[8] B.Q. Saeed, R. Al-Shahrabi, S.S. Alhaj, *et al.*

Side effects and perceptions following Sinopharm COVID-19 vaccination

Int J Infect Dis, 111 (2021), pp. 219-226

View PDF View article View in Scopus ↗

Google Scholar ↗

[9] S.R. Harrison, J.R.L. Klassen, C. Bridgewood, *et al.*

Chest pain mimicking pulmonary embolism may be a common presentation of COVID-19 in ambulant patients without other typical features of infection

J Intern Med, 290 (2021), pp. 349-358

CrossRef ↗ View in Scopus ↗

Google Scholar ↗

[10] D. McGonagle, C. Bridgewood, A.V. Ramanan, *et al.*

COVID-19 vasculitis and novel vasculitis mimics

Lancet Rheumatol., 3 (2021), pp. e224-e233

View PDF View article View in Scopus ↗

Google Scholar ↗

[11] N.H. Schultz, I.H. Sørvoll, A.E. Michelsen, *et al.*

Thrombosis and thrombocytopenia after ChAdOx1 nCoV-19 vaccination

N Engl J Med, 384 (2021), pp. 2124-2130

CrossRef ↗ View in Scopus ↗

Google Scholar ↗

[12] D. McGonagle, G.D. Marco, C. Bridgewood
Mechanisms of immunothrombosis in vaccine-induced thrombotic thrombocytopenia (VITT) compared to natural SARS-CoV-2 Infection
J Autoimmun, 121 (2021), Article 102662
View PDF View article View in Scopus ↗
Google Scholar ↗

[13] J. Finsterer
Neurological side effects of SARS-CoV-2 vaccinations
Acta Neurol Scand, 145 (2022), pp. 5-9
CrossRef ↗ View in Scopus ↗
Google Scholar ↗

[14] J.B. Schulz, P. Berlit, H.C. Diener, *et al.*
COVID-19 vaccine-associated cerebral venous thrombosis in Germany
Ann Neurol, 90 (4) (2021), pp. 627-639
CrossRef ↗ View in Scopus ↗
Google Scholar ↗

[15] T. Iba, J.H. Levy, T.E. Warkentin
Recognizing vaccine-induced immune thrombotic thrombocytopenia
Crit Care Med, 50 (1) (2022), pp. e80-e86
CrossRef ↗ Google Scholar ↗

[16] R. Hosseini, N. Askari
A review of neurological side effects of COVID-19 vaccination
Eur J Med Res, 28 (2023), p. 102
View in Scopus ↗ Google Scholar ↗

[17] S.A. Assiri, R.M. Althaqafi, K. Alswat, *et al.*
Post COVID-19 vaccination-associated neurological complications
Neuropsychiatr Dis Treat, 18 (2022), p. 137
CrossRef ↗ View in Scopus ↗
Google Scholar ↗

[18] C.J. Woo, O.H.I. Chou, B.M.Y. Cheung
Ramsay Hunt syndrome following COVID-19 vaccination
Postgrad Med J, 98 (1164) (2022), pp. 738-739
CrossRef ↗ Google Scholar ↗

Cited by (0)

© 2023 International Hemorrhagic Stroke Association. Publishing services by Elsevier B.V. on behalf of KeAi Communications Co. Ltd.

We use cookies to help provide and enhance our service and tailor content and ads. By continuing you agree to the **use of cookies**.
All content on this site: Copyright © 2023 Elsevier B.V., its licensors, and contributors. All rights are reserved, including those for text and data mining, AI training, and similar technologies. For all open access content, the Creative Commons licensing terms apply.